

Resurfacing with a new 675-nm laser device: A case series

To the Editor,

Laser resurfacing procedures are constantly increasing, and they have largely replaced other aesthetic procedures such as peeling and dermabrasion.¹ Laser technologies in this area have also evolved from ablative lasers to nonablative lasers, which stimulate dermal fibroblasts to produce new collagen that lead to reduction of skin wrinkles and improvement of skin texture.²

In fact, with aging, degradation of collagen and an abnormal accumulation of elastin in the dermis can be observed; this process causes loss of elasticity, resulting in an increase of wrinkles and accumulation of melanin, generating dyschromia.

The 675-nm RedTouch laser (Deka Me.La, Italy) is a promising nonablative laser in this field. The system is based on the emission

of a wavelength of 675nm (red light) through a scanning system of 15 × 15-mm able to generate a selective thermal damage on the skin with an average depth of 300 microns, reaching the dermis. At this level, the thermal impulse produced causes denaturation of collagen fibers with consequent formation of new collagen.

For this reason, RedTouch is particularly suitable for acne scars, dyschromia, and resurfacing. While for the first two indications there already are data in literature discussing efficacy and various protocols, the same is not available for resurfacing with 675 nm laser.^{3,4}

Therefore, with the purpose of providing real-life data on the effectiveness and results in laser-based resurfacing at 675 nm, in this report we present our experience with 29 patients (19 women and

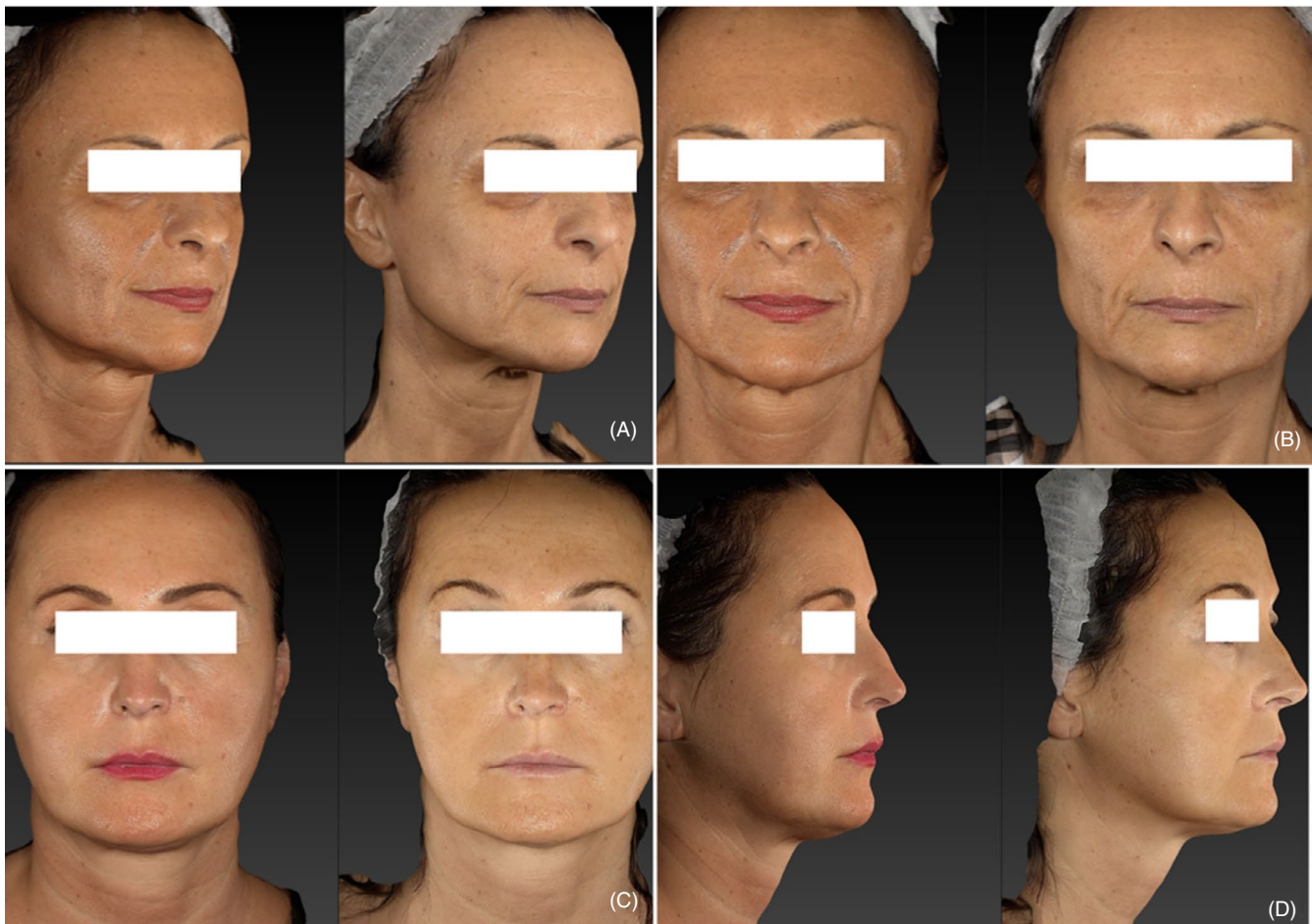

FIGURE 1 (A,B) Lateral and frontal view; the increased production of collagen is clearly visible after the second session with improvement of nasolabial folds and marionette lines. (C,D) Frontal and lateral view of pre- and post-treatment; skin texture is improved, and jawline areas have been redefined

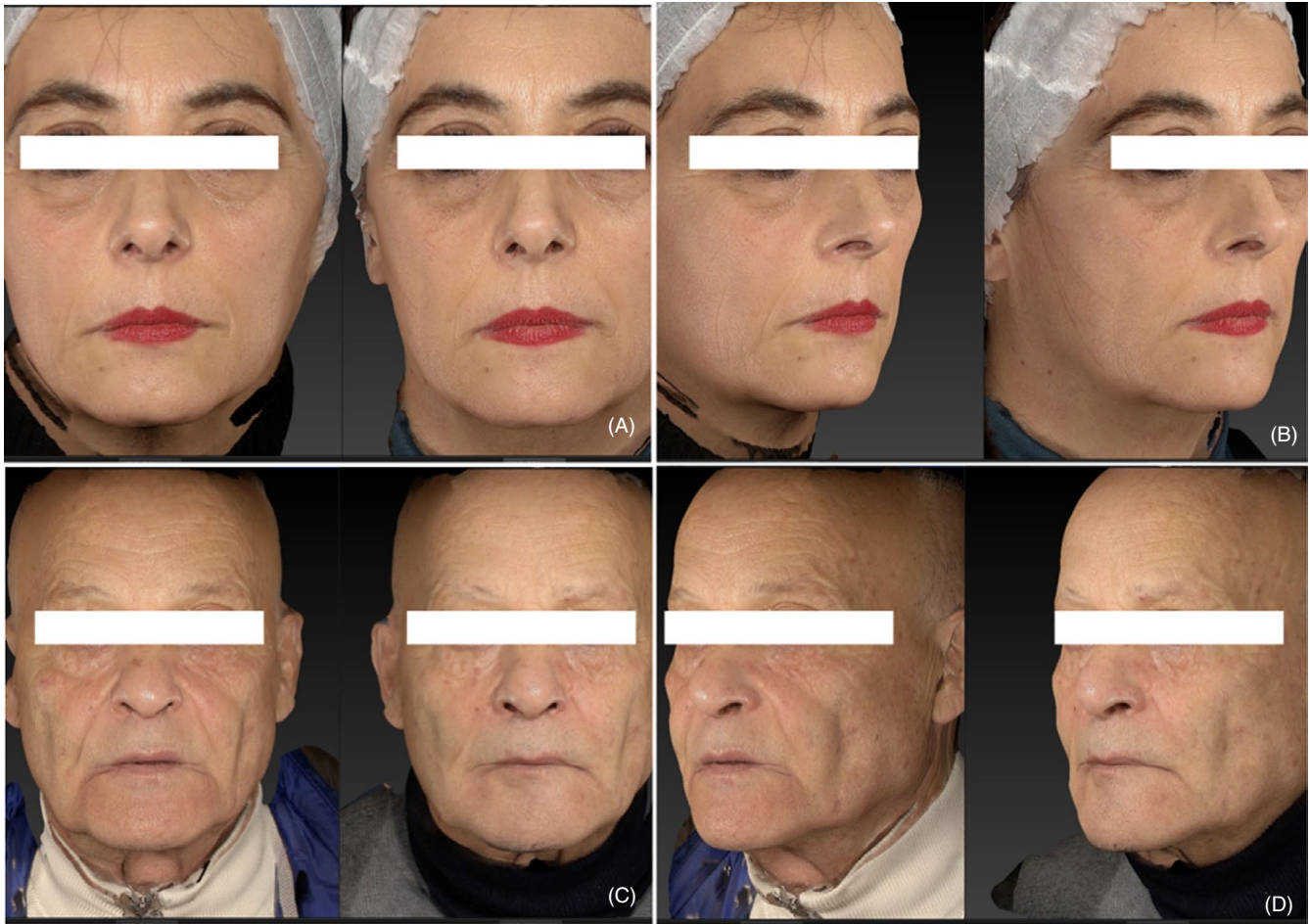

FIGURE 2 A, Frontal view, after and before treatment with 675nm laser B, detail of the improvement of nasolabial folds and jawline area. C,D, Frontal and later view; in the zygomatic area, reduction of deep wrinkles can be observed

10 men) with an mean age of 52 years (range 47-66) treated with two sessions at 30 days apart from each other.

All patients were photographed using Vectra 3D software at the beginning, after the first session and immediately and after the second treatment. Results are shown in Figure 1 and Figure 2.

Each session was preceded by an appropriate alcoholic and non-alcoholic facial cleansing to disinfect the skin, cleanse the sebum, and mechanically remove the stratum corneum.

The used protocol was based on the following setting: power 10.0 W, d-well time 150 ms, and spacing 1000 micron.

An improvement in skin texture was achieved for all patients. A greater cutaneous tone was noted in the lower third of the face, with a reduction of chin-labial wrinkles (so-called marionette lines) and redefinition of jawline area, since the first session. The increased production of collagen is clearly visible after the second session in which a tensor effect of the zygomatic region, also leading to a reduction of nasolabial folds, was obtained. Indirectly, we observed an improvement in skin elasticity in the periocular area where, in case of brownish dark circles under the eyes, RedTouch showed a good response, due to its action on melanic dermal deposits.

The strength of this treatment is the absence of downtime and serious side effects. A slight erythema after treatment can be observed, but thanks to a cooling system of the laser maniple, the epidermis is protected from thermal damage. For this reason, patients can immediately return to their daily activities without affecting the quality of life (QoL).


These results not only promise a rapid spread of this technology but are also the starting point for combined treatments with the aim to treat more complex diseases that require integrated approaches such as atrophic acne scars or severe facial wrinkles.

KEYWORDS

675nm, aesthetic dermatology, laser, resurfacing

CONFLICT OF INTEREST

Authors declare to have no conflict of interests.

Domenico Piccolo MD¹
Dimitra Kostaki MD¹
Giuliana Crisman MD¹
Claudio Conforti MD² 

¹*Skin Centers, Avezzano-Pescara, Italy*

²*Dermatology Clinic, University of Trieste, Trieste, Italy*

Correspondence

Claudio Conforti, Dermatology Clinic, Maggiore Hospital of
Trieste, Trieste 34125, Italy.

Email: claudioconforti@yahoo.com

ORCID

Claudio Conforti  <https://orcid.org/0000-0001-5126-8873>

REFERENCES

1. Pozner JN, DiBernardo BE. Laser resurfacing: full field and fractional. *Clin Plast Surg*. 2016;43(3):515-525.

2. Conforti C, Zalaudek I, Vezzoni R, et al. Chemical peeling for acne and melasma: current knowledge and innovations. *G Ital Dermatol Venereol*. 2020;155(3):280-285.
3. Cannarozzo G, Silvestri M, Tamburi F, et al. A new 675-nm laser device in the treatment of acne scars: an observational study. *Lasers Med Sci*. 2020.
4. Nisticò SP, Tolone M, Zingoni T, et al. A New 675 nm Laser Device in the Treatment of Melasma: Results of a Prospective Observational Study. *Photobiomodul Photomed Laser Surg*. 2020;38(9):560-564.

How to cite this article: Piccolo D, Kostaki D, Crisman G, Conforti C. Resurfacing with a new 675-nm laser device: A case series. *J Cosmet Dermatol*. 2021;20:1343-1345. <https://doi.org/10.1111/jocd.13916>